

Callosal Microstructure Correlates With Upper Limb Motor Outcome in Moderate-to-Severe Stroke

Ja Eun Koo^{1*}, Eun Joo Lee¹, Eun Jin Park¹, Eun ji Lee¹, Sun Jae Won¹, So-youn Chang^{1†}, Youngkook Kim^{1,2‡}

¹Department of Rehabilitation Medicine, Yeouido St. Mary's Hospital, College of Medicine, The Catholic University of Korea

²Department of Rehabilitation Medicine, RIS Rehabilitation Clinic, 60, Godeokbizvalley-ro 2ga-gil, Gangdong-gu, Seoul, Republic of Korea

Background & Objective

Upper limb motor outcome after moderate-to-severe stroke shows substantial interindividual variability that is not fully explained by corticospinal tract (CST) integrity alone. Structural pathways supporting interhemispheric connectivity, such as the corpus callosum (CC), may provide complementary information.

Methods

This retrospective cohort study included 38 patients with first-ever middle cerebral artery ischemic stroke and moderate-to-severe impairment (Table 1). Diffusion tensor imaging was performed during the early subacute phase (7 days to 3 months post-stroke). Fractional anisotropy (FA) values of the CST and CC subregions (genu, body, splenium) were obtained, and CC FA values were normalized to the contralesional CST to derive corrected CC FA. Upper limb motor outcome was assessed using the Shoulder Abduction and Finger Extension (SAFE) score at 3 and 6 months post-stroke. Associations between neuroimaging markers and motor outcomes were examined using simple and multiple linear regression analyses adjusting for age and lesion volume.

Results and Conclusion

At 3 months post-stroke, the CST FA laterality index ($R = 0.666$, $p < 0.001$), lesion volume ($R = 0.387$, $p = 0.018$), and corrected FA of the genu ($R = 0.371$, $p = 0.024$), body ($R = 0.395$, $p = 0.016$), and splenium ($R = 0.392$, $p = 0.016$) were significantly associated with SAFE scores (Table 2). In multiple linear regression models, CC microstructure of each subregion remained independently associated with upper limb motor outcome beyond CST integrity at 3 months, with adjusted R^2 values of 0.602 for the genu, 0.535 for the body, and 0.532 for the splenium (all $p < 0.001$; Table 3A).

At 6 months post-stroke, corrected FA of the CC subregions continued to show independent associations with SAFE scores beyond CST integrity. The strongest association was observed for the genu (adjusted $R^2 = 0.647$, $p < 0.001$), followed by the body (adjusted $R^2 = 0.541$, $p < 0.001$) and splenium (adjusted $R^2 = 0.546$, $p < 0.001$; Table 3B).

These findings indicate that corpus callosum microstructure, particularly within the genu, is independently associated with upper limb motor outcome beyond CST integrity in patients with moderate-to-severe stroke. Interhemispheric white matter integrity provides complementary structural information for understanding variability in post-stroke motor outcomes.

Table 1. Demographic and Clinical Characteristics of the Patients

Characteristics	Patients (N=38)
Age, years	73.74±11.93
Female sex, n (%)	19 (50)
Stroke characteristics	
Left hemisphere lesion, n (%)	24 (60.16)
Lesion volume, cm ³	51.29±64.50
Clinical characteristics	
Fazekas scale, total* (range 0-6)	3 (1-4)
NIHSS score, initial	11.00±5.41
MMSE (range 0-30) at IRF admission	14.68±9.88
MBI (range 0-100) at IRF admission	25.03±24.40
Modified Rankin Scale* at IRF admission	5 (4-5)
Data acquisition	
DTI acquisition, days [†]	27.08±20.55

Abbreviations: NIHSS, National Institutes of Health Stroke Scale; MMSE, Mini-Mental State Examination; IRF, inpatient rehabilitation facility; MBI, Modified Barthel Index; DTI, diffusion tensor imaging.

*Median value (interquartile range)

[†]Days since stroke onset.

Values are expressed as the mean±standard deviation, unless otherwise stated.

Table 2. Association Between the Clinical variables & Neuroimaging biomarkers and Shoulder Abduction and Finger Extension (SAFE) Score using Simple Linear Regression Analyses.

	R	R ²	t	P-value
Clinical variables				
Age	0.287	0.082	1.770	0.085
Lesion volume	0.387	0.150	-2.483	0.018
Neuroimaging biomarkers				
CST FA laterality index*	0.666	0.443	5.275	<0.001
Corpus callosum				
Genu [†]	0.371	0.138	2.364	0.024
Body [†]	0.395	0.156	2.545	0.016
Splenium [†]	0.392	0.154	2.522	0.016

Abbreviations: t, t test statistic; CST FALI, FA laterality index of the corticospinal tract (CST) measured at the pontomedullary junction; FA, fractional anisotropy.

* CST FA laterality index = $(FA_{\text{damaged}} - FA_{\text{non-damaged}}) / (FA_{\text{damaged}} + FA_{\text{non-damaged}})$

[†] corrected FA values using non-damaged CST FA.

Table 3. Multiple Linear Regression Models Examining the Association Between the Shoulder Abduction and Finger Extension (SAFE) Score and Structural Integrity of the Corpus Callosum subregions.

(A) 3 Months Post-Stroke

Models	Adjusted R ²	Significant variables	Unstandardized		Standardized		
			B	SE	β	t	P-value*
Genu of corpus callosum [†]	0.602 [‡]	CST FALI [§]	15.629	2.890	0.581	5.408	<0.001
		Age	0.092	0.027	0.373	3.360	0.002
		Genu	10.728	3.171	0.381	3.384	0.002
Body of corpus callosum [†]	0.535 [‡]	CST FALI [§]	15.528	3.189	0.577	4.869	<0.001
		Age	0.072	0.028	0.290	2.530	0.016
		Body	7.867	3.476	0.270	2.263	0.030
Splenium of corpus callosum [†]	0.532 [‡]	CST FALI [§]	15.374	3.229	0.572	4.761	<0.001
		Age	0.074	0.029	0.300	2.584	0.014
		Splenium	6.161	2.804	0.267	2.197	0.035

(B) 6 Months Post-Stroke

Models	Adjusted R ²	Significant variables	Unstandardized		Standardized		
			B	SE	β	t	P-value*
Genu of corpus callosum [†]	0.647 [‡]	CST FALI [§]	17.064	3.497	0.587	4.879	<0.001
		Age	0.079	0.031	0.309	2.518	0.019
		Genu	13.023	3.749	0.430	3.474	0.002
Body of corpus callosum [†]	0.541 [‡]	CST FALI [§]	17.925	4.014	0.616	4.465	<0.001
		Body	10.354	4.673	0.306	2.216	0.036
		Splenium of corpus callosum [†]	0.546 [‡]	CST FALI [§]	17.125	4.093	0.589
Splenium	8.688	3.802		0.322	2.285	0.031	

Abbreviations:

B, unstandardized beta coefficients; SE, standard error; β , standardized beta coefficients; t, t test statistic; CST FALI, FA laterality index of the corticospinal tract (CST) measured at the pontomedullary junction; FA, fractional anisotropy.

* indicates the significance of independent variable

[†] corrected FA values using non-damaged CST FA

[‡] indicates significant models with $P < 0.001$.

[§] CST FALI = $(FA_{\text{damaged}} - FA_{\text{non-damaged}}) / (FA_{\text{damaged}} + FA_{\text{non-damaged}})$

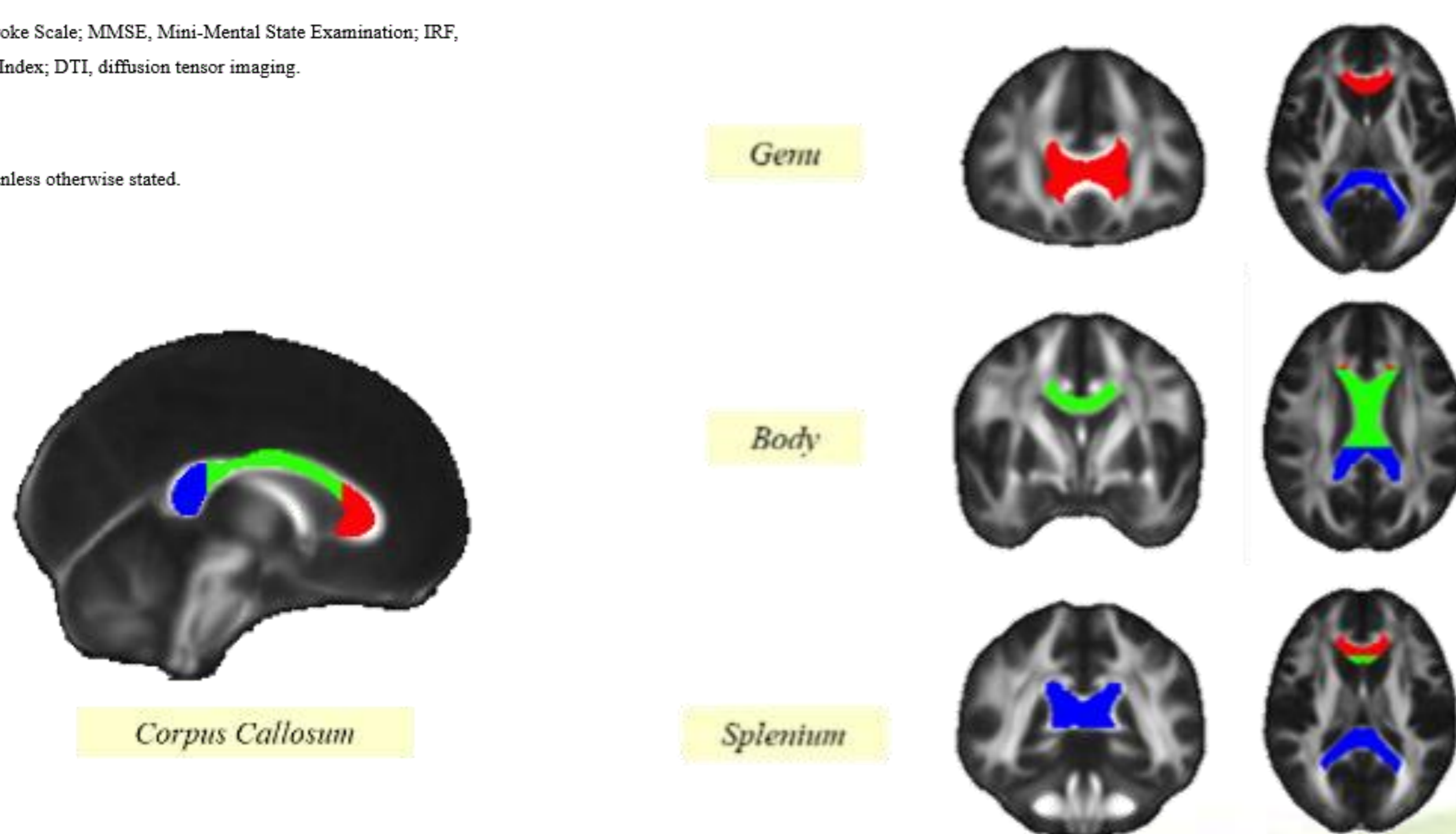


Figure 1. Regions of interest (ROIs) used to evaluate the microstructural integrity of the genu, body, splenium of the corpus callosum (CC) on diffusion tensor imaging.