

# Brachial Plexus Palsy and Horner Syndrome Following Cervical Schwannoma Resection: A Two-Case Report

Ji Yun Kim, Hong Bum Park, Ki Hoon Kim

Department of Physical Medicine and Rehabilitation, Korea University College of Medicine

## INTRODUCTION

Cervical schwannomas are benign nerve sheath tumors that arise from Schwann cells along cervical nerve roots or the brachial plexus. Although surgical excision is curative, proximity to critical neural structures such as the brachial plexus and cervical sympathetic chain can lead to iatrogenic neural complications, including brachial plexus palsy and Horner syndrome.

We present two cases of cervical schwannoma resection complicated by distinct neurological sequelae, with detailed electrodiagnostic and functional follow-up from a rehabilitation medicine perspective.

## CASE 1

### Case Diagnosis

A 52-year-old man had a long-standing posterior neck mass first noted in 2019, which gradually enlarged and was accompanied by tingling in the left upper limb. Preoperative MRI showed a 6.9-cm cystic lesion in the left posterior triangle. On April 28, 2025, he underwent excision of an approximately 8-cm cystic mass encasing the brachial plexus, and pathology confirmed schwannoma with cystic degeneration.

### Case Description

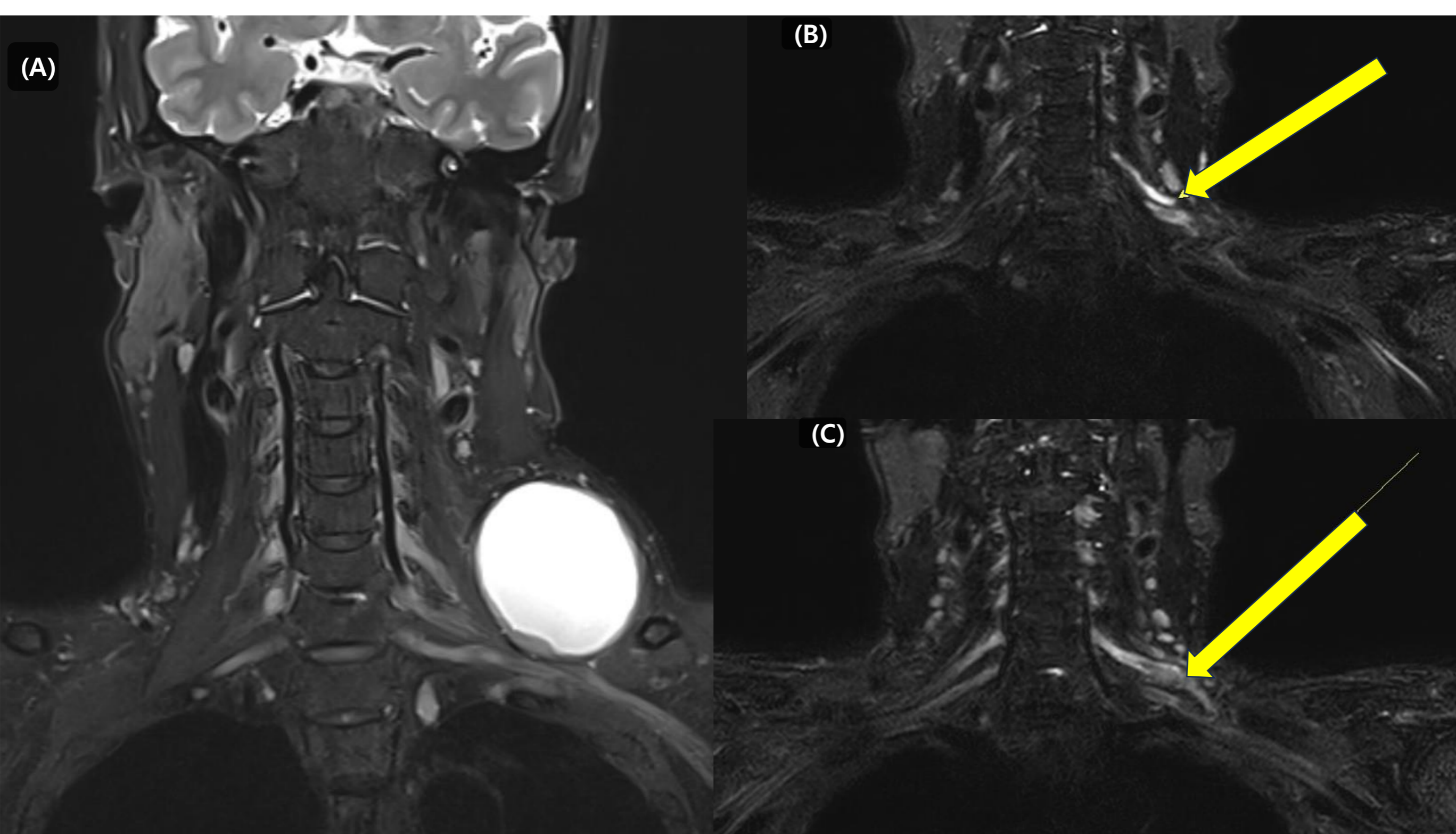
Immediately after surgery, he showed severe proximal-predominant weakness of the left upper limb (shoulder flexion/abduction: MRC 1–2, elbow flexion: 3, elbow extension: 4, wrist and hand: near-normal). On follow-up at 5 months postoperatively, manual muscle testing demonstrated partial recovery (shoulder flexion/abduction: MRC 2–3, elbow flexion/extension: 4, wrist and hand: 5).

Motor NCS showed persistently low axillary (0.8–1.5 mV) and musculocutaneous (2.1–2.7 mV) amplitudes throughout follow-up. Serial needle EMG findings are summarized in Table 1. Postoperative brachial plexus MRI showed suspected left C5 root discontinuity with marked swelling of the C6 root and superior cord, compatible with a left C5–C6 root/upper trunk brachial plexopathy (Figure 1).

**Table 1. Serial Needle EMG Findings of the Left Upper Limb**

Muscle	POD 4 (05.02)	POD 11 (05.09)	POD 38 (06.05)	POD 157 (10.02)
Deltoid	No MUAP	No MUAP	Fib/PSW 1+ No MUAP	Fib/PSW 1+ Single/Disc
Biceps	Polys, Small Max R	Small Max R	Fib/PSW 2+ Large, Max R	Fib/PSW 2+ Large, Mod R
Infraspinatus	No MUAP	No MUAP	Fib/PSW 1+ No MUAP	Fib/PSW 1+ No MUAP
Supraspinatus	-	-	-	Fib/PSW 1+ No MUAP
Pronator teres	Min R	-	Fib/PSW 1+ Large, Mod R	Long dur Mod R
Brachioradialis	-	-	Fib/PSW 2+ Single/Disc	Distant

Serial electrodiagnostic studies were performed at postoperative days 4, 11, 38, and 157. Muscles innervated by the C5 and C6 roots (upper trunk) were followed serially. Denervation signs (fibrillation potentials and positive sharp waves) appeared in the subacute phase, and reinnervation potentials (large-amplitude, long-duration motor unit action potentials with improved recruitment) were subsequently observed in selected muscles, particularly the biceps brachii and pronator teres.



**Figure 1.** (A) Preoperative neck MRI. Initial imaging suggested a non-neoplastic cystic lesion such as 3rd branchial cleft cyst or cystic lymphangioma in the left posterior triangle; however, surgical pathology confirmed schwannoma with cystic change. (B, C) Postoperative brachial plexus MRI. (B) Suspected broken left C5 nerve root (yellow arrow). (C) Marked swelling with irregular margin and angulation of the left C6 nerve root and the superior cord (yellow arrow).

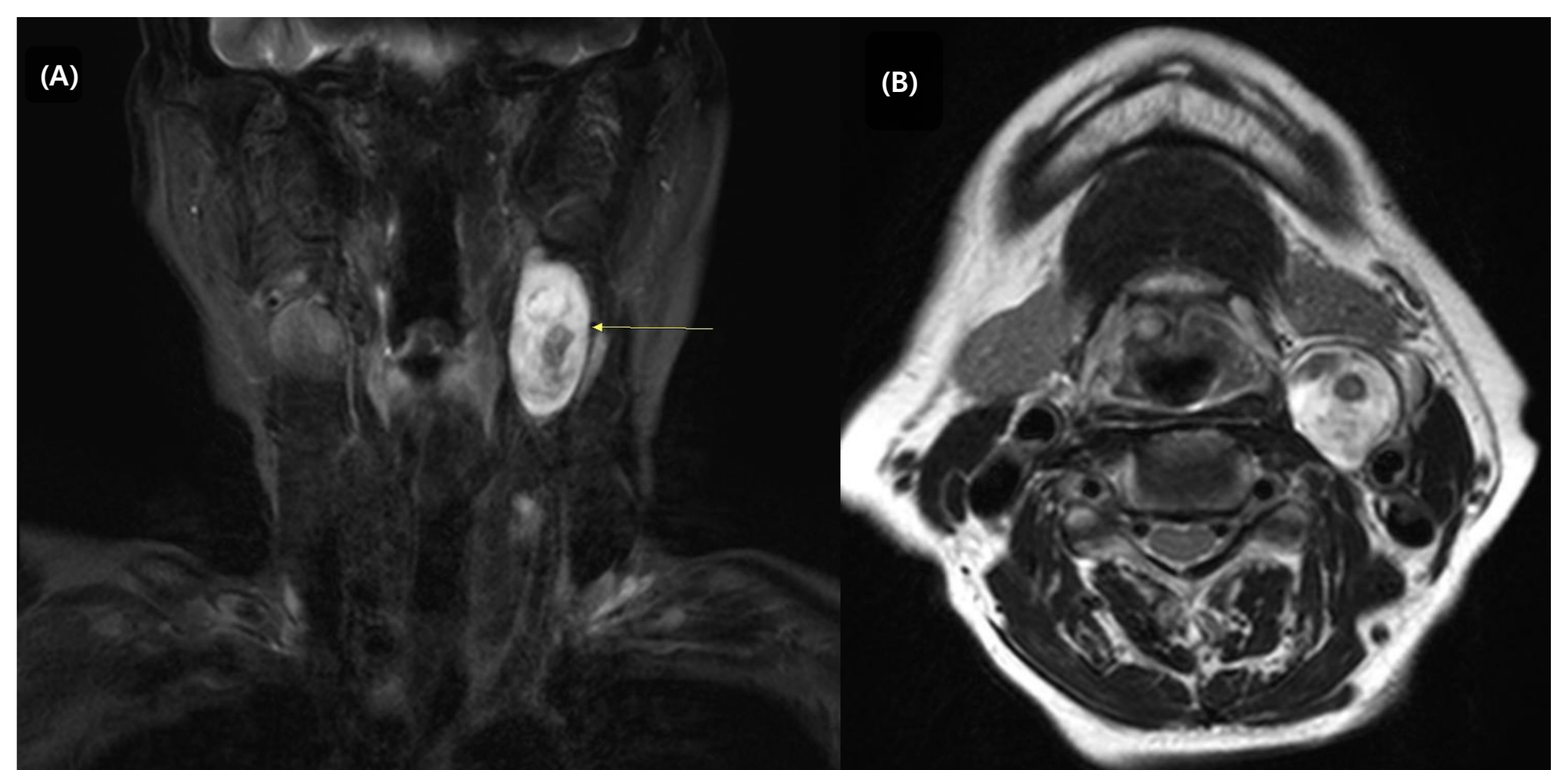
## CASE 2

### Case Diagnosis

A 78-year-old woman noticed a left neck mass in May 2019. Neck CT/MRI showed a 4.6-cm lesion in the left parapharyngeal space, suspicious of a neurogenic tumor. On September 20, 2019, she underwent transcervical excision of a 4-cm parapharyngeal tumor after balloon occlusion test confirmed safety of carotid occlusion. Pathology confirmed a benign schwannoma.

### Case Description

Postoperatively, she developed ipsilateral ptosis consistent with iatrogenic Horner syndrome, while limb motor and sensory examinations remained normal. Because of persistent discomfort from left ptosis, she underwent corrective surgery on May 17, 2021, with improvement.



**Figure 2.** (A, B) Preoperative neck MRI showing a 4.6 × 2.4 × 1.8 cm T2 inhomogeneously hyperintense ovoid mass in the left parapharyngeal space with posterior displacement of the left carotid artery, suggestive of a neurogenic tumor.

## DISCUSSION

These cases demonstrate that neurologic complications following benign cervical schwannoma surgery may persist beyond the acute postoperative phase and require continued rehabilitation involvement.

In Case 1, shoulder and elbow strength improved with rehabilitation, supported by serial MRC grading and electrodiagnostic evidence of partial reinnervation. However, deltoid atrophy caused shoulder instability, requiring surgical reconstruction. This highlights the role of rehabilitation physicians in monitoring neurology and detecting secondary complications. In Case 2, persistent ptosis from Horner syndrome produced functional and cosmetic concerns, leading to surgical correction. This emphasizes the importance of recognizing autonomic complications and their functional impact to guide appropriate multidisciplinary management.

## CONCLUSION

These cases underscore the essential role of rehabilitation physicians in managing cervical schwannoma patients. Serial electrodiagnostic studies are critical for tracking nerve recovery and predicting prognosis. Rehabilitation physicians coordinate conservative care and facilitate timely referral when residual deficits require surgical intervention. Close multidisciplinary collaboration are essential to optimize long-term functional outcomes.