

INCOMPLETE RECOVERY OF ANEURYSM-RELATED OCULOMOTOR NERVE PALSY AFTER REPEATED FLOW DIVERTER TREATMENT

Seung Gue Choi, M.D, Jeong Hoo Lee, M.D
Department of Rehabilitation Medicine, Presbyterian Medical Center (Jesus Hospital)

BACKGROUND

- Oculomotor nerve palsy (ONP) is a known complication of intracranial aneurysms.
- Recovery depends on timing and severity of nerve compression.
- Even after flow diverter (FD) treatment, persistent deficits may occur.
- However, recovery after repeated FD treatment has not been well described.
- This case emphasizes the importance of continuous neurologic monitoring by physiatrists and the transition to compensatory rehabilitation when structural recovery is limited.

CASE DESCRIPTION

1. Clinical Timeline (Fig. 1)

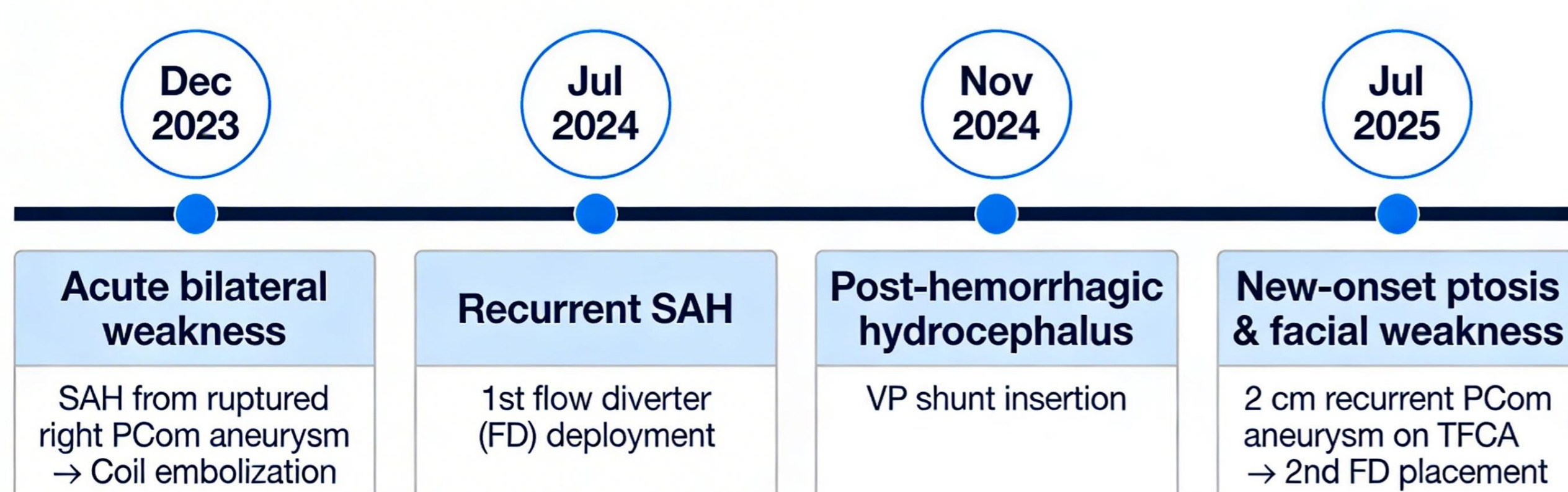


Figure 1. Timeline of recurrent aneurysm and repeated flow diverter treatment.

- A 62-year-old woman presented with acute bilateral upper and lower extremity weakness.
- Dec 23, 2023: Subarachnoid hemorrhage (SAH) with ruptured right posterior communicating artery (PCom) aneurysm → Coil embolization
- Jul 5, 2024: Recurrent SAH → 1st FD placement
- Nov 18, 2024: Post-hemorrhagic hydrocephalus → VP shunt insertion
- Jul 28, 2025: New-onset ptosis & facial weakness → Transfemoral Cerebral Angiography (TFCA) revealed 2 cm recurrent aneurysm → 2nd FD placement (Fig. 2)

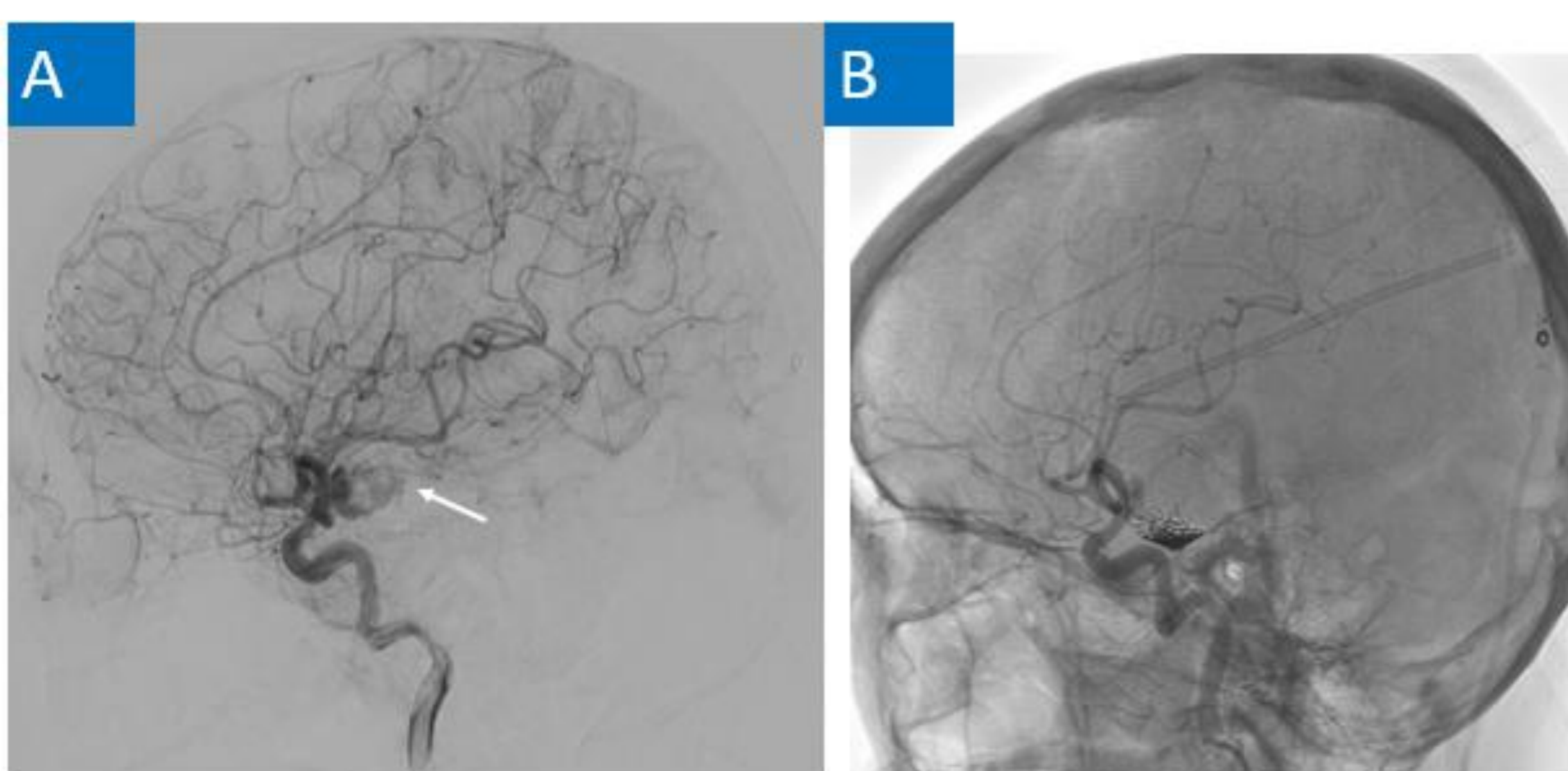


Figure 2. (A) TFCA demonstrating a recurrent PCom aneurysm (arrow). (B) After placement of second FD, no residual flow into the aneurysm is observed.

2. Neurologic Examination (Post-treatment)

- Despite repeated FD treatments, persistent ONP remained. (Figure 3)
- Symptoms: Ptosis, Diplopia
- Eye movement function
 - Limitation: Adduction, Elevation, Depression
 - Preserved: Abduction
- Clinical Interpretation: Structural stabilization achieved, but functional recovery limited by neural compression.

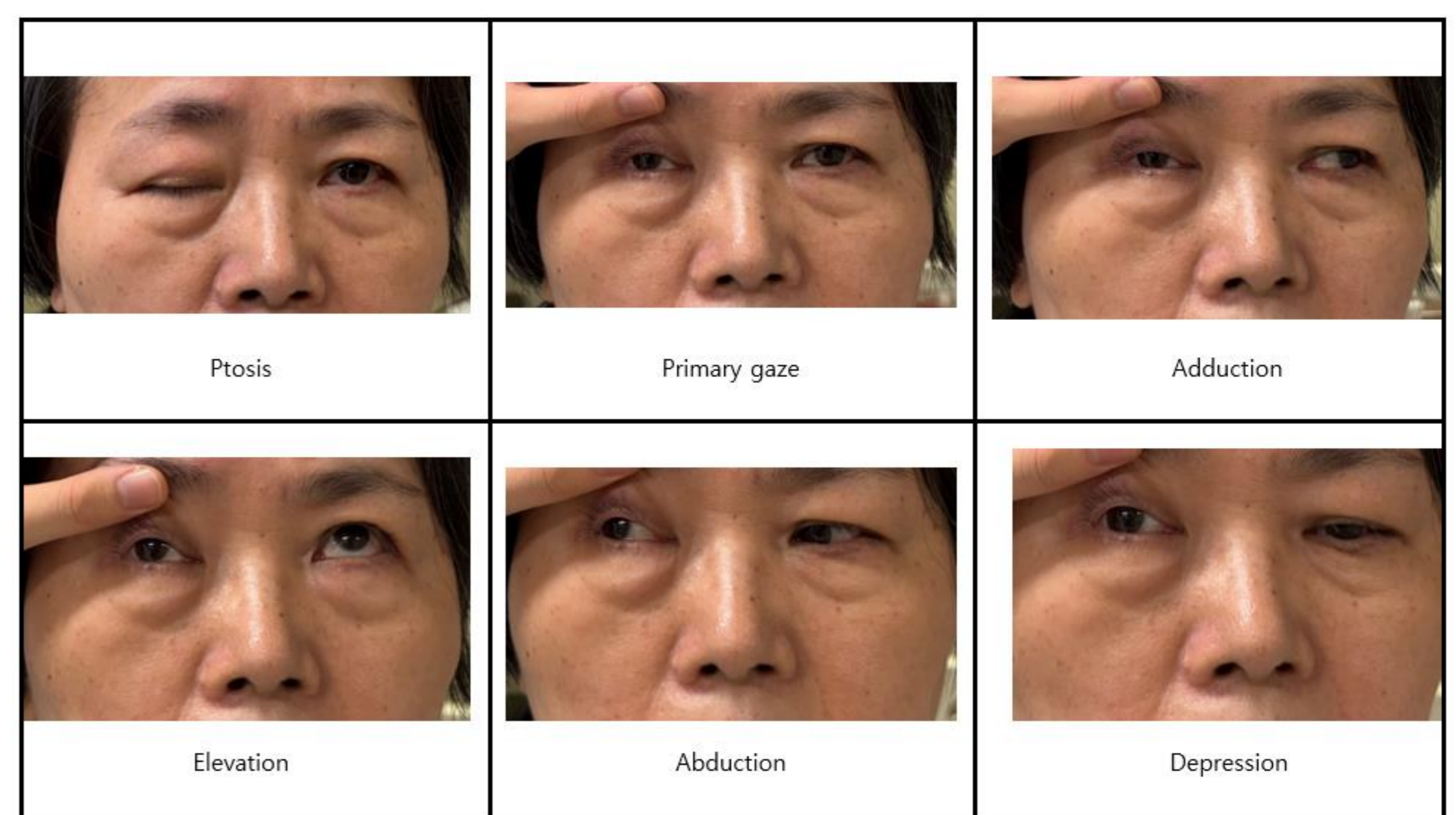


Figure 3. Right oculomotor nerve palsy, including ptosis and limitation of eye movements, including adduction, elevation, and depression

3. Rehabilitation Interventions

- Extraocular Muscles exercise
- Diplopia management using monocular patch
- Compensatory Strategies: Head-turn training to optimize the functional visual field
- Visual scanning training to enhance spatial awareness
- Adaptation to monocular cues for depth perception and safety in daily activities

CONCLUSIONS

- **Continuous Monitoring:** Essential for detecting recurrence and tailoring physiatrist-led rehabilitation.
- **Prognostic Limitation:** Persistent ONP may not fully resolve despite successful repeated endovascular interventions.
- **Compensatory Focus:** Rehabilitation should focus on compensatory strategies to maximize functional independence and Quality of Life.

Reference

1. Abo Kasem R, Cunningham C, Elawady SS, et al. Oculomotor nerve palsy recovery following microsurgery vs. endovascular treatment of posterior communicating artery aneurysms: a comparative meta-analysis of short- and long-term outcomes. *Neurosurg Rev.* 2024;47(1):904. Published 2024 Dec 18. doi:10.1007/s10143-024-03149-7
2. Talebnejad MR, Sharifi M, Nowroozzadeh MH. The role of Botulinum toxin in management of acute traumatic third-nerve palsy. *J AAPOS.* 2008;12(5):510-513. doi:10.1016/j.jaapos.2008.03.009