

Na Yoon Yoo¹, Hyoung Seop Kim¹, Joong Won Yang², Dougho Park³

¹Department of Physical Medicine and Rehabilitation, National Health Insurance Service Ilsan Hospital, Goyang, South Korea

²Department of Neurosurgery, Pohang Stroke and Spine Hospital, Pohang, South Korea

³Department of Rehabilitation Medicine, Pohang Stroke and Spine Hospital, Pohang, South Korea

Background

Schwannoma occurring within the psoas muscle is rare, and only a few case reports have been reported. The surgical approach to removing schwannoma in the psoas muscle is challenging because the potential injury can be applied to the lumbar plexus due to its anatomical proximity.

Intraoperative neurophysiological monitoring (IONM) is a diagnostic tool that enables real-time detection of nerve damage during surgery. Even in surgery with the possibility of peripheral nerve injury, the functional integrity of nerves can be confirmed by using the direct nerve stimulation method within the surgical field. In this case report, we report a case of safe removal of a schwannoma in the psoas muscle using IONM.

Case Report

A 31-year old man complained of right side back pain and anterolateral thigh numbness for two months. The patient's lumbar spine magnetic resonance imaging revealed a mass lesion in the right psoas muscle at the level of second to fourth lumbar vertebrae. (Fig.1 (A),(B)) The surgeon performed the removal of the mass under general anesthesia, and the mass was confirmed as a schwannoma histologically.

During the operation, free-running EMG, evoked EMG and motor evoked potential were recorded from the target muscles; vastus medialis, adductor magnus, tibialis anterior, and abductor hallucis muscles. Mild burst pattern was observed in the free-running EMG of the right abductor hallucis (Fig.2A). However, there was no neurotonic discharge corresponding to neuronal injury. Compound motor nerve action potential was observed in the trigger EMG of the right adductor magnus and vastus medialis around the medial margin of the tumor (Fig. 2B), but direct integration of the motor nerve was not present in the intra-tumor region. In addition, somatosensory evoked potential of right lateral femoral cutaneous nerve was recorded, and there was no change of amplitude and latency during the operation.

There was no root lesion or peripheral nerve lesion in the electromyography studies which were performed before and after the surgical intervention. A month after the surgery, there was improvement of anterolateral thigh numbness and right back pain.

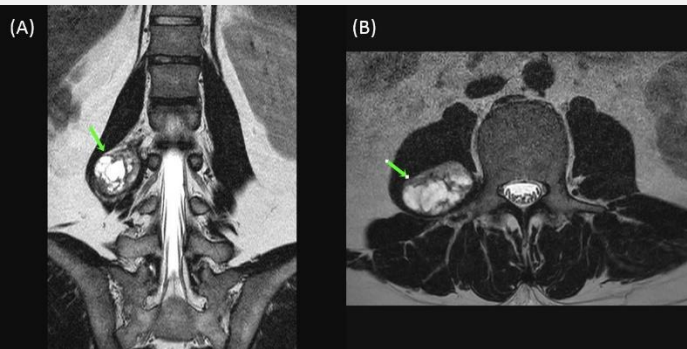


Fig. 1. Preoperative magnetic resonance imaging (MRI) findings. A well-demarcated mass lesion in the right psoas muscle was shown in the (A) coronal and (B) axial views of MRI. (Arrows)

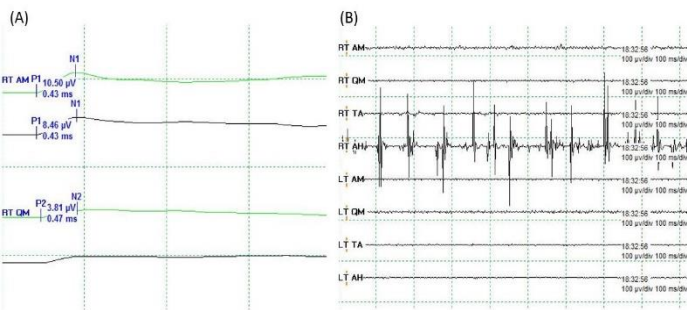


Fig. 2. Intraoperative neurophysiological monitoring findings.

(A) Mild burst patterns are shown in the right abductor hallucis.

(B) Direct stimulation with maximal stimulation (25mA) evoked compound motor nerve action potentials in the right adductor magnus and vastus medialis.

Conclusion

The presented case confirms that removal of schwannoma in the psoas muscle, which is adjacent to the lumbar plexus, can be performed safely under IONM.