



Optimized Trans-Cranial Direct Current Treatment for a Patient with Titanium Mesh ; Case report

Kyung Hyun Park, M.D. 1, Sun Im, M.D., Ph.D.1*, Geun-Young Park, M.D., Ph.D.1, Seungyup Song, M.D. 1, Hyungtaek Kim, M.S.2, Jongseung Lee, M.S.2, TaeYeong Kim, P.T., Ph.D.2, Seong Hoon Lim, M.D., Ph.D.3,

¹ Department of Rehabilitation Medicine, Bucheon St. Mary's Hospital, College of Medicine, The Catholic University of Korea

² Research Institute, NEUROPHET, Inc., Seoul, Republic of Korea

³ Department of Rehabilitation Medicine, St. Vincent's Hospital, College of Medicine, The Catholic University of Korea

Introduction

Transcranial direct current stimulation (tDCS) has shown potential to restore awareness in patients with minimal consciousness (MCS). Most brains of patients in MCS state have severe damage structurally and electro physiologically. Thus, neuro modulation with the conventional EEG 10-20 system has several neurophysiological limitations for patients with MCS. We present our experience with a patient with prolonged MCS and severe brain damage, who had undergone cranioplasty with titanium mesh, but was treated with tDCS with simulation and optimization based on using the patient's brain magnetic resonance image (MRI). The treatment proved to be successful resulting in emergence from MCS and significant neurological improvement.

Case

A 62-year-old woman underwent a series of operations for subarachnoid hemorrhage with a ruptured posterior communicating artery, including coil embolization, decompressive craniectomy, ventriculoperitoneal shunt, and cranioplasty with a titanium mesh (Figure 1). Following the operations, the patient was diagnosed with MCS, and her revised coma recovery scale (CRS-r) score was 3 (A0V0M2O0C0Ar1).

One year later attempts for non-invasive neuromodulation treatment to improve the patient's level of consciousness was discussed. However, due to the conductivity of the titanium mesh, conventional neuromodulation with tDCS was not considered as a treatment option. Under the consensus and agreement from all her legal guardians, she underwent treatment with tDCS to facilitate the dorsolateral prefrontal cortex (DLPFC). We simulated the electric field and locations for targeting the right DLPFC via Neurophet's TesLab based on the patient's MRI. Simulation with the conventional 10-20 system revealed the Enorm of the target was lower, and the area of maximal Enorm shifted from the right DLPFC to the interhemispheric area (Figure 2, left). The electric field for stimulations with optimization on MRI showed the proper Enorm of right DLPFC (Figures 2, right). After the patient treated with ten consecutive optimized tDCS sessions, she woke up with a CRS-r score of 17 (A2V4M3O3C2Ar1). Two months later, she showed dramatic neurological recovery including nasogastric tube weaning and able to start full oral feeding. She also showed improvement in communication and truncal control.

Conclusion

For many years, the 10-20 system has been used for non-invasive neuro modulation. However, this system only provides an approximate location. Studies have shown that blinded treatment with the 10-20 system for primary motor cortex using repetitive transcranial magnetic stimulation (rTMS) failed to produce statistical therapeutic effects on motor function in patients with subacute stroke, while guided rTMS using 120-channel EEG for refractory epilepsy resulted in a reduction in epilepsy frequency. The skull and scalp act as high-frequency and low-frequency filters. In this case, subarachnoid hemorrhage and several neurosurgical procedures altered the brain structure, while cranioplasty with titanium mesh further disrupted the filters. This case report provides evidence that patients with metallic surgical procedures can undergo successful tDCS treatment with dramatic neurological recovery after proper optimization based on a personalized and guided approach.

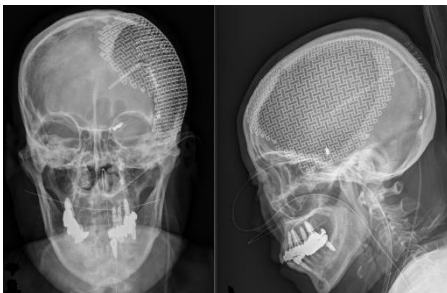


Figure 1. Anteroposterior and lateral plain X-rays. The X-rays demonstrate the titanium mesh covering the left cranium.

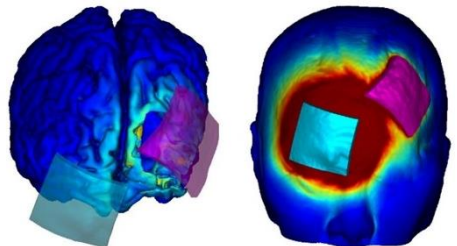


Figure 2. Simulation and the locations by conventional and optimization for targeting the right dorsolateral prefrontal cortex. The red pad is the cathode, and the blue pad is the anode. Simulation shows that the Enorm values of right dorsolateral prefrontal cortex were stimulated by tDCS via two methods. The left is simulation via conventional stimulation with 10-20 system, The right is simulation via optimization based on the patient's MRI.