

Background

- Bainbridge-Ropers syndrome (BRPS) is caused by various pathogenic variants in the ASXL3 (Additional sex combs-like3) gene and is characterized by generalized developmental delay including intellectual and language disturbance with dysmorphic face.
- The ASXL3 gene is in the ASXL family including ASXL1 and ASXL2, assumed to act as a histone methyl transferase that is related to hereditary neurological disorders.
- Since the first report in 2013, about 90 cases have been reported up to date.
- We present two novel heterozygous variants in ASXL3 and compare the phenotypes and prognoses.

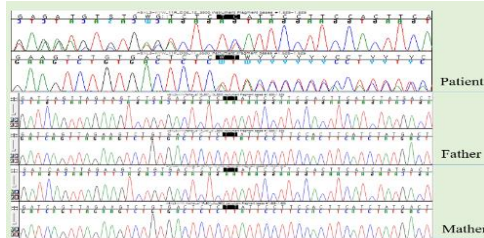


Figure 1. The sanger sequencing of the ASXL3 of case1 patient and his parents. A novel de novo frameshift variant was found in ASXL3 gene.

Case 1

- A 19-month-old boy showed generalized developmental delay with language and cognitive delay.
- The Bayle Scales represented below 0.1% percentile of development in all domains cognition 8 months, language development 7 months, fine motor 8 months, and gross motor 10 months of age.
- He had a dysmorphic face and skeletal deformities such as Down-slanting palpebral fissures, long nasal bridge, prominent forehead, micrognathia, club foot, flexion contracture of finger joints (Table 1).
- The brain MRI showed no abnormality.
- The Next-Generation Sequencing (NGS) revealed a novel heterozygous frameshift deletion variant in ASXL3 c.1628_1629del / p.(Leu543HisfsTer12) (Figure 1).
- With continuous rehabilitation, At the 4-year-old, he could gait independently and presented some improvement in cognition and adaptive functions.

Case 2

- A 6-year-8-months-old girl suffered generalized developmental delay with language and cognitive dysfunction.
- At the 7-year-8-month-old, all of the development were evaluated as 5 to 9 months of age by Bayle Scales. The Gross Motor Function Measure (GMFM) scored 26.4% and the SQ was 6.02.
- She had features such as facial dysmorphism such as down-slanting palpebral fissure, high palate, micrognathia and articular dislocations and scoliosis but did not show limb deformities (Table 1).
- The whole genome sequencing was conducted and it revealed a novel heterozygous deletion-insertion variant in exon 11 of ASXL3 g.33740509_33743845delinsAGAAGCCTAGGTGTAC.
- Despite continuous rehabilitation including physical and occupational therapy, At the 18-year-old, GMFM score showed a comprehensive score of 15.15%, which is lower than the initial evaluation. She could not even stand by herself.

Table 1. Previously reported variants, craniofacial dysmorphism, clinical features and brain images of patients with Bainbridge Ropers syndrome.

	Bainbridge et al. (2)	Kuechler et al. (4)	Kris et al. (5)	Koboldt et al. (6)	Schaida et al. (7)	Case 1	Case 2
Number of probands	4	6	4	2	6	1	1
ASXL3 variant	c.1210C>T c.1396C>T c.1422dup c.1978_1981del	c.1219delA c.1369G4T c.3106C4T c.3494_3495delGT c.3613G4T c.4072_4073delGT	c.5307 A>T c.5455C>T c.1377_1378del c.4399C>T	c.3106C>T	g.31320159_31320160del c.4534C>T c.4441dup	c.1628_1629del	g.33740509_33743845 del ins GAAAGCCTAGGTGTAC
Inheritance	De novo	De novo	De novo	De novo	Unknown 2 De novo 1 Paternally inherited 1 Maternally inherited 2	De novo	De novo
Craniofacial dysmorphic features	Forehead, frontal bossing, large fontanels, arched, thin eyebrows, high narrow palate, low posteriorly rotated ears, microcephaly, retrognathia, long eyelashes, short nose, hypertelorism, hypopropia, prominent, antverted nares	Prominent forehead, arched eyebrows, downslanting palpebral fissures, strabismus, downturned corners of the mouth, high, narrow palate, prominent columella, antverted nares, little facial expression with open mouth appearance, microcephaly	Hypertelorism, downslanting palpebral fissure, arched eyebrows, prominent forehead, broad nasal tip, antverted nostril, everted lower lip, high arch palate, open mouth appearance, little facial expression, cleft lip/palate, microcephaly	Long face, rectangular forehead, downslanting palpebral fissures, abnormality of the pinna, prominent nasal bridge, underdeveloped nasal alae, broad nasal tip, macrodontia of permanent maxillary central incisor, high narrow palate, cleft of chin, micrognathia	Down-slanting palpebral fissures, prominent forehead, columella, high narrow palate, micrognathia, small teeth, premature closure of fontanelles, microcephaly, long eyelashes, prominent nasal bridge, small mouth	Downslanting palpebral fissures, long nasal bridge, prominent supraorbital ridge, micrognathia, ptosis, thin lips, open mouth appearance	Downslanting palpebral fissures, high palate Micrognathia
Clinical features	Feeding difficulty, global developmental delay, intellectual disability, hypotonia, ulnar deviation, deep palmar creases, clenched hands, undescended testes, exotropia, hirsutism, supernumerary nipple	Feeding difficulty, poor sucking, global developmental delay, speech delay, tachy/apnea, long & slender fingers, ulnar deviation, pectus excavatum, hirsutism, poor eye contact, Stiff finger joints	Feeding difficulty, intellectual disability, psychomotor delay, speech delay, autistic features, hypotonia, gastroesophageal reflux, ulnar deviation, camptodactyly, insulina resistance	Feeding difficulty, autistic features, intellectual disability, global developmental delay, language delay, recurrent hand flapping, short stature, clinodactyly, hirsutism	Feeding difficulty, global developmental delay, speech delay, temper tantrums, sleep apnea, dilated subclavian artery, Arachnodactyly, Scoliosis, Short first and fifth metacarpals, Incomplete palmar crease	Global developmental delay, speech delay, intellectual disability, hypotonia, calcaneal varus, pes planus, flexion contracture of left 3rd and 4th finger (PIP), extension posture of lower limbs, hydrosphrosis	Global developmental delay, speech delay, intellectual disability, hypotonia, hip and knee dislocation, spinal scoliosis, knee contracture, ankle tightness, gait disturbance
Brain MRI findings	Global mild white-matter volume loss with normal myelination, secondary brainstem hypoplasia	Hypoplasia of cerebellar vermis	Prominent sylvian fissures, axia axial CSF	Hypoplasia of corpus callosum, Ventriculomegaly	Prominence of the right temporal horn and volume loss of the right hippocampal region	Not definite	Frontal lobe atrophy

Conclusion

- This study compared the phenotypic differences between two completely distinct types of heterozygous novel variants within the ASXL3 gene. The copy number variant case demonstrated milder facial and limb abnormalities, but poor prognosis