

Torticollis with Paracondylar Process : A Case Report



Hyun Ji Hwang¹, Hae-ri Park¹, Jeewon Yoon¹, Seung Mi Yeo^{1*}

Department of Rehabilitation Medicine, Pusan National University Yangsan Hospital¹

Introduction

PARACONDYLAR PROCESS

- Enlarged occipital bone projecting toward the transverse process of atlas (C1)
- Rare developmental anatomical variant and numerous variations in size and clinical presentation
- Finding confirmed incidentally through x-ray or computed tomography (CT), usually without specific symptoms

When there is paracondylar process, there are very few cases where chief complain is torticollis. We report the case of a 12-year-old girl with torticollis due to paracondylar process.

Case report

- A 12-year-old girl
- Chief complain : Right lateral shift of neck (Fig. 1) that became aware of 3 years ago
- Absence of traumatic event or intervention
- In order to solve this problem, it was reported that there was no improvement in head correction treatment at a Korean medicine clinic for more than 2 years.
- Absence of any other symptoms including pain and limitation of movement
- Normal range of motion of neck on physical examination
- No motor weakness of upper extremities on physical exam
- Normoactive deep tendon reflexes of upper extremities on physical exam

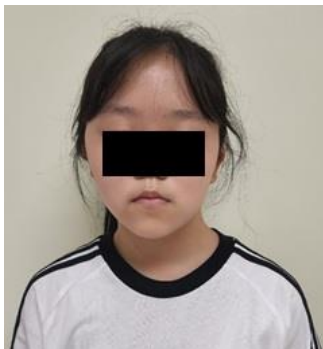

Figure 1. Head posture tilted to left side and translated to right side.

- In the CT image, anomalous articulation of the **occipital bone** and **atlas** was confirmed, and it was revealed that **pseudoarthrosis** was formed, not syntheses.
- Atlantoaxial subluxation was not observed, but **rotation of the axis to the right relative to the atlas** was confirmed (Fig. 2, 3).
- She was referred to the neurosurgery department right after the diagnosis and the surgical treatment was not necessary.

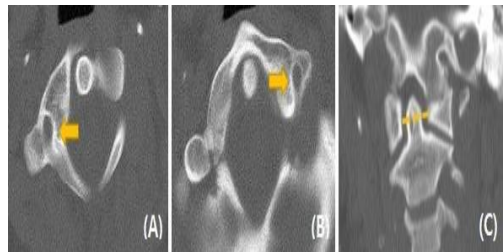


Figure 2. Computed tomography images of cervical spine. (A), (B) In a transverse view, because of tilting of atlanto-axial joint each transverse foramen of C2 cannot be shown in the same plane. (C) Coronal view shows asymmetric lateral atlanto-axial interval.

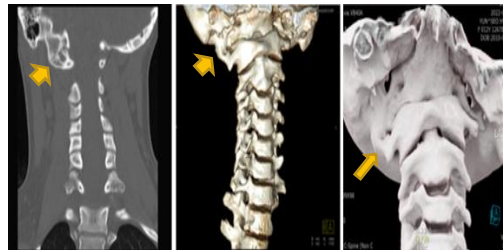

Figure 3. Three dimensional computed tomography images of cervicovertebral junction. Occipital bone and paracondylar process makes pseudoarthrosis but there is no rotatory atlantoaxial subluxation.

Conclusion

- In our case, 12-year-old girl showed torticollis without other symptoms.
- Even with the long-term physical therapy, the torticollis didn't show significant improvement.
- The anomalous articulation was found in plain radiography and paracondylar process was confirmed on CT images.
- In conclusion, even if paracondylar process is rare and normally asymptomatic, it should be taken into consideration in the patients with torticollis.